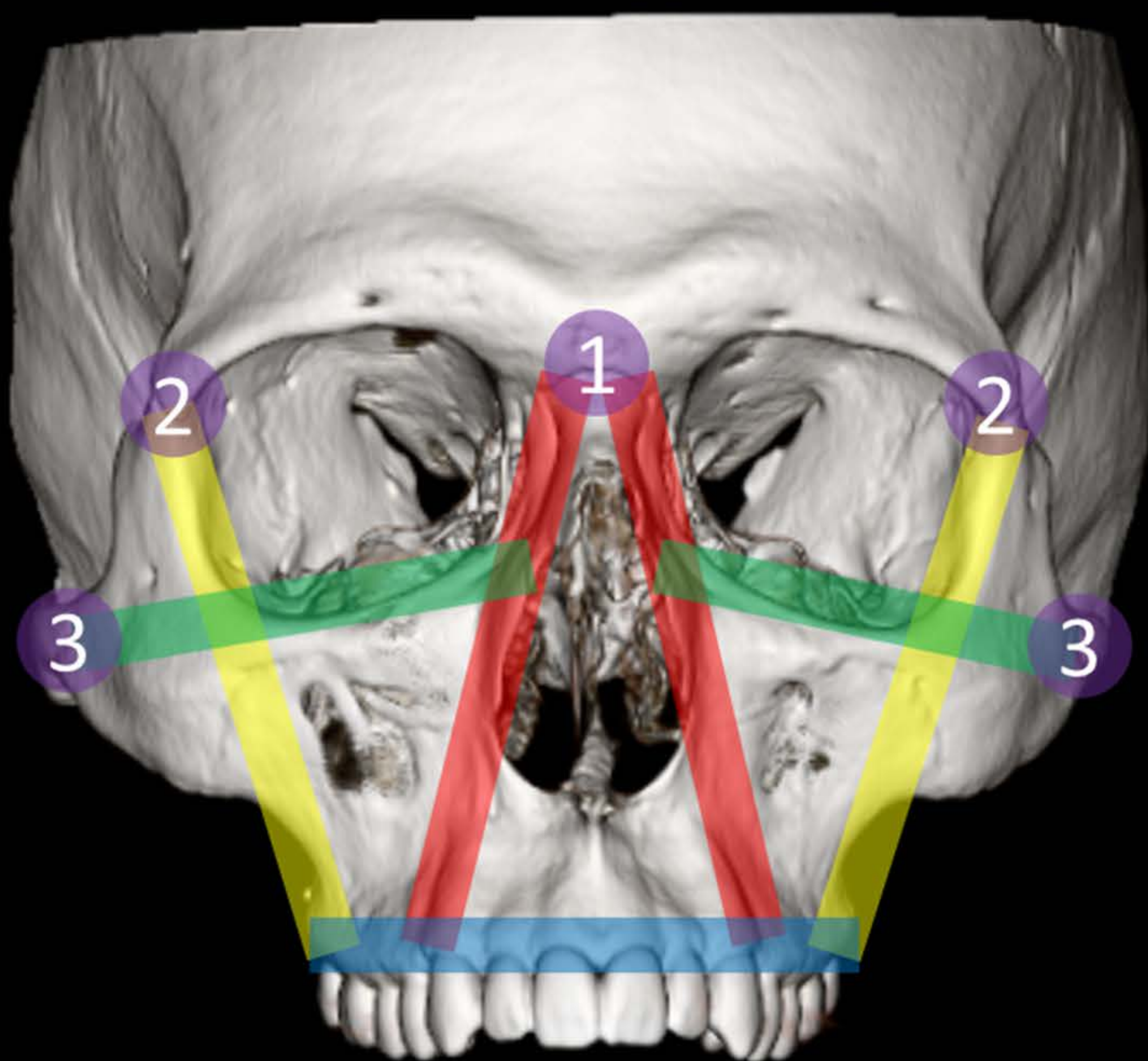


# Complex Facial Fractures

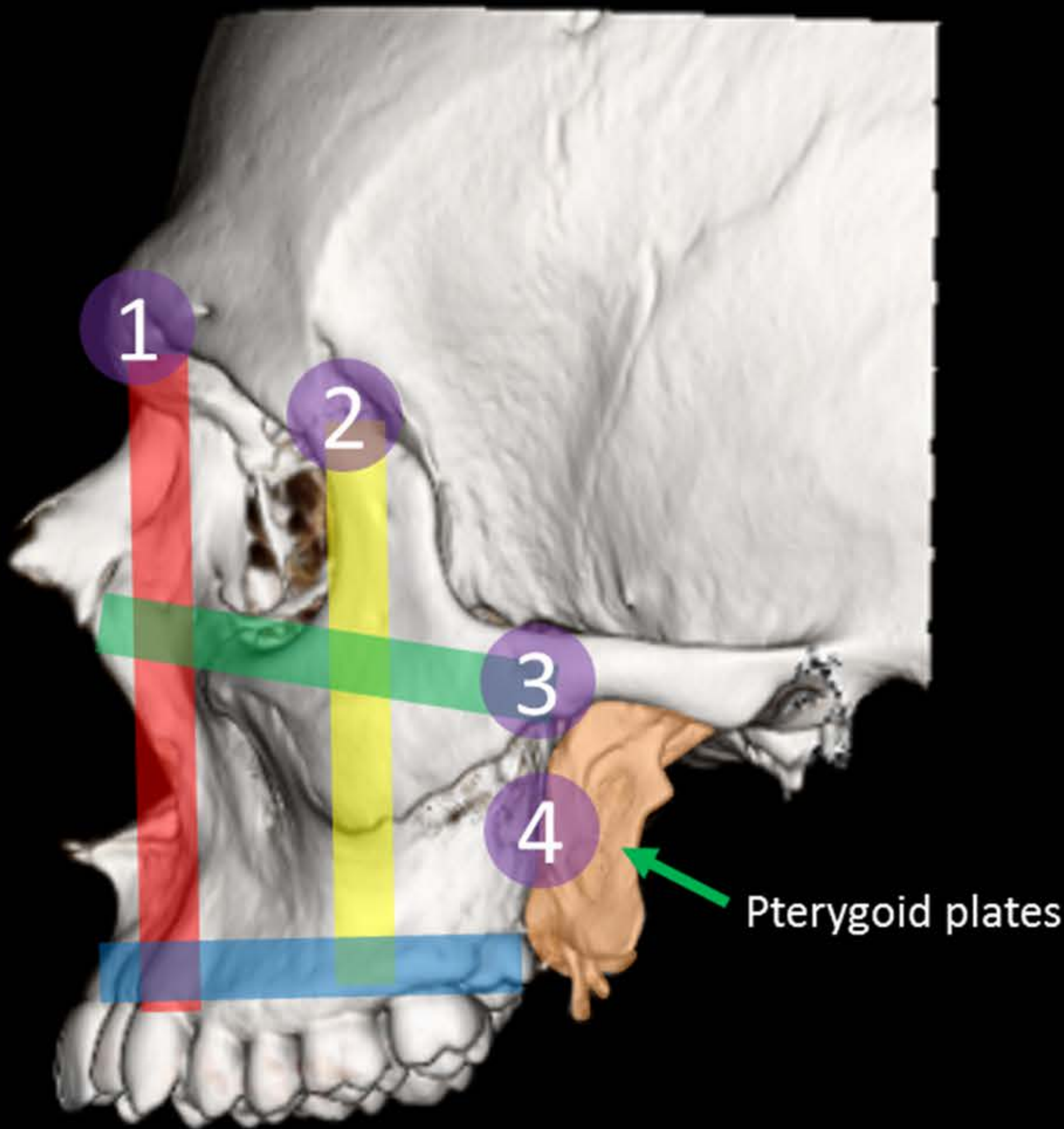
Surgeons think about the face as a system of buttresses and anchors. The approach to complex facial fractures boils down to assessing the integrity of this structural framework. Study the figure below and then work through the different patterns of complex facial fractures below and to the right, focusing on buttress and anchor disruption associated with each fracture pattern.

\*Please be aware that the surgical repairs shown here are meant to be illustrative and are not always what is done.



Midface buttresses

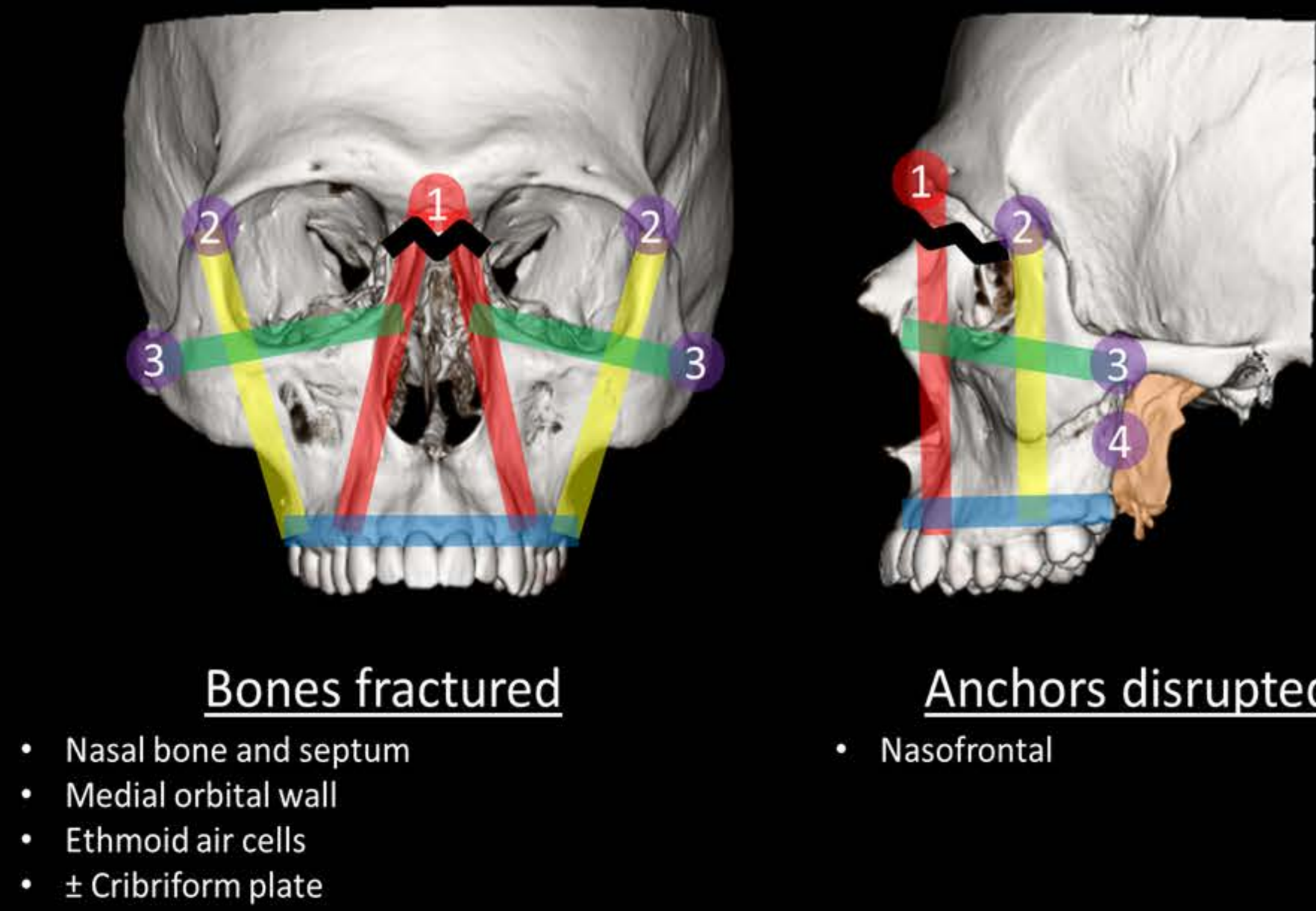
- Upper transverse maxillary
- Lower transverse maxillary
- Medial maxillary
- Lateral maxillary



Midface anchors

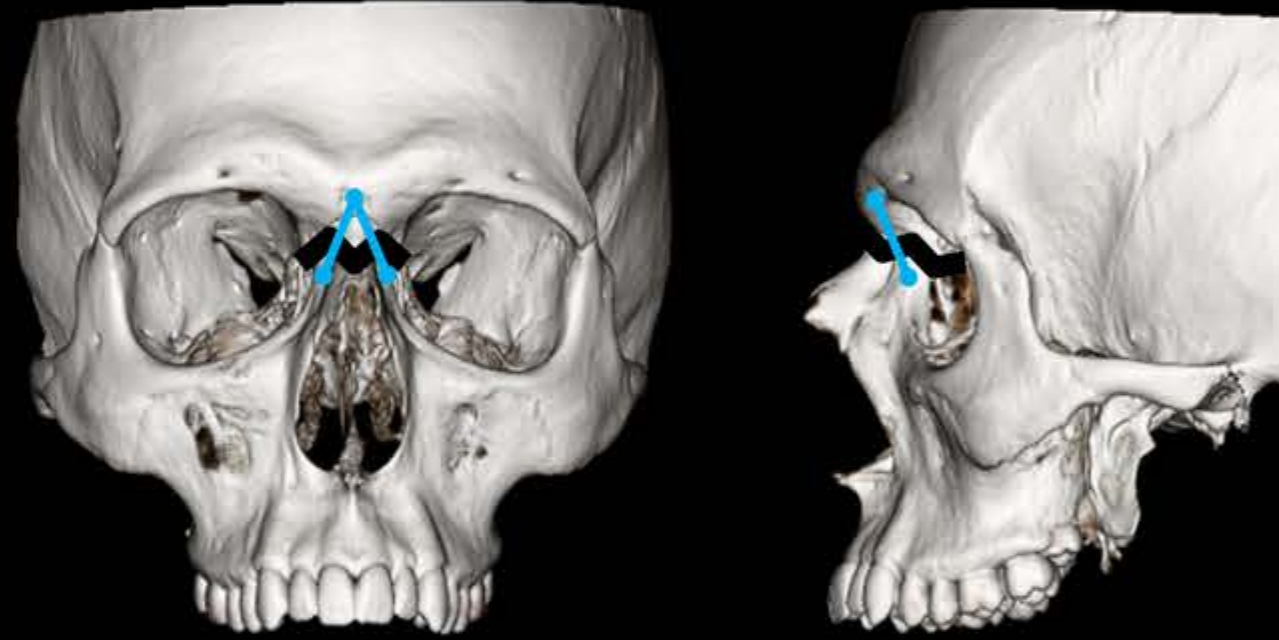
- 1 Nasofrontal suture
- 2 Zygomaticofrontal suture
- 3 Zygomaticotemporal suture
- 4 Pterygomaxillary /pterygopalatine

## Nasoorbitoethmoid (NOE)

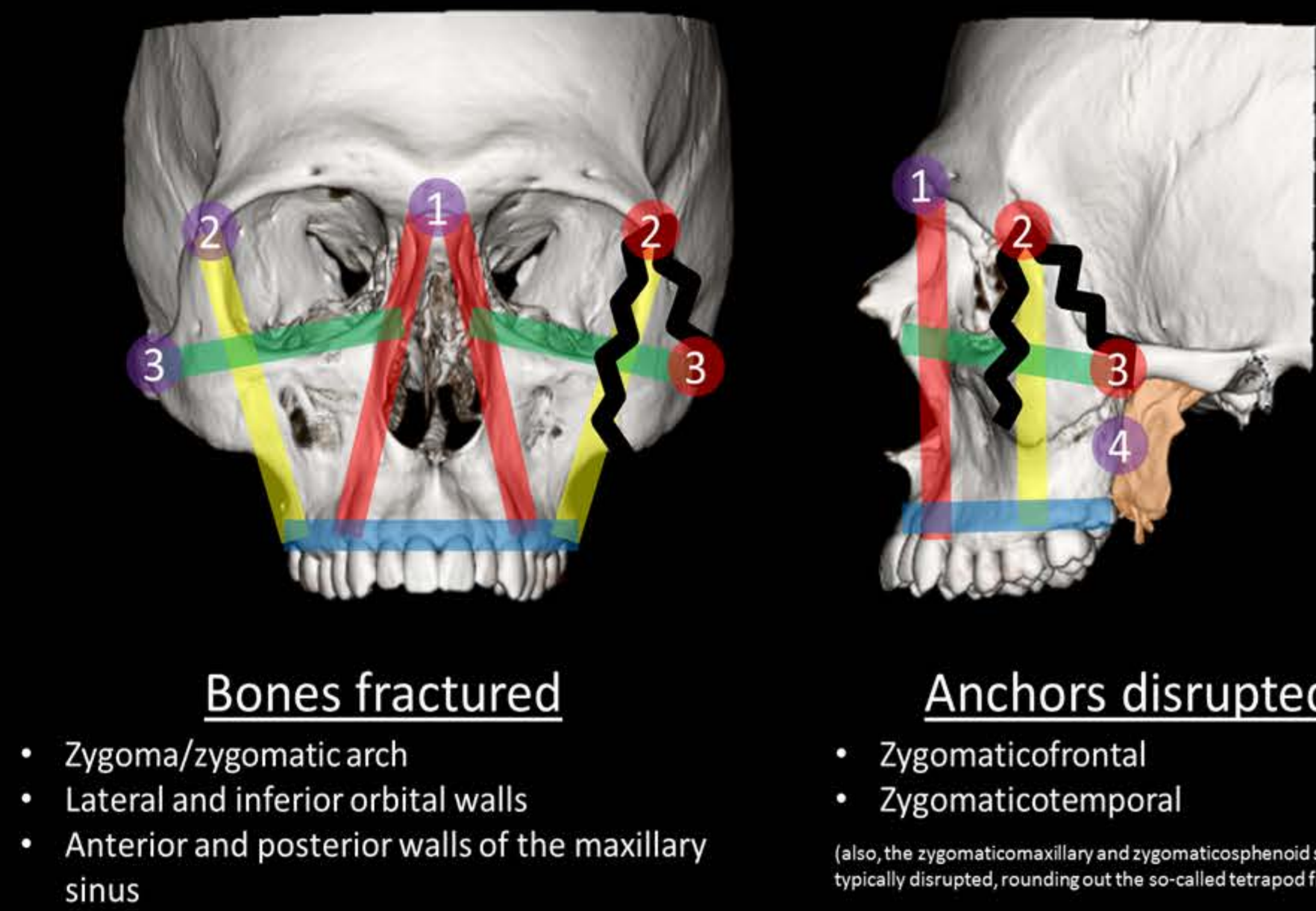


- Bones fractured**
  - Nasal bone and septum
  - Medial orbital wall
  - Ethmoid air cells
  - ± Cribriform plate
- anchors disrupted**
  - Nasofrontal

### Surgical Repair



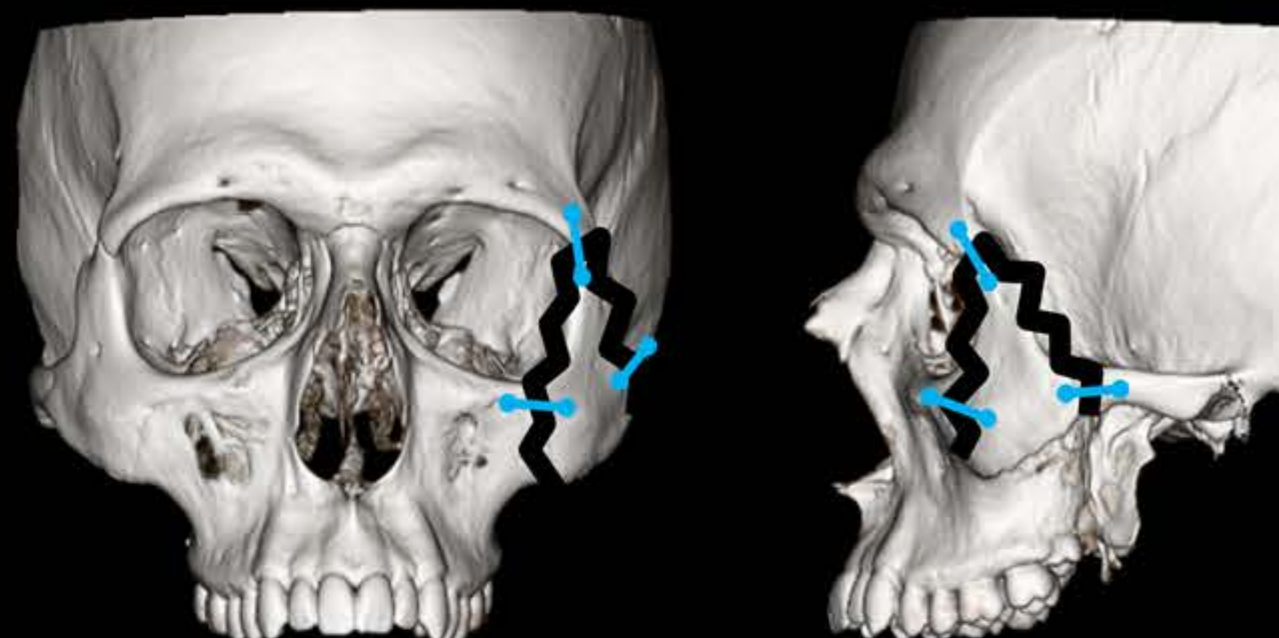
## Zygomaticomaxillary Complex (ZMC)



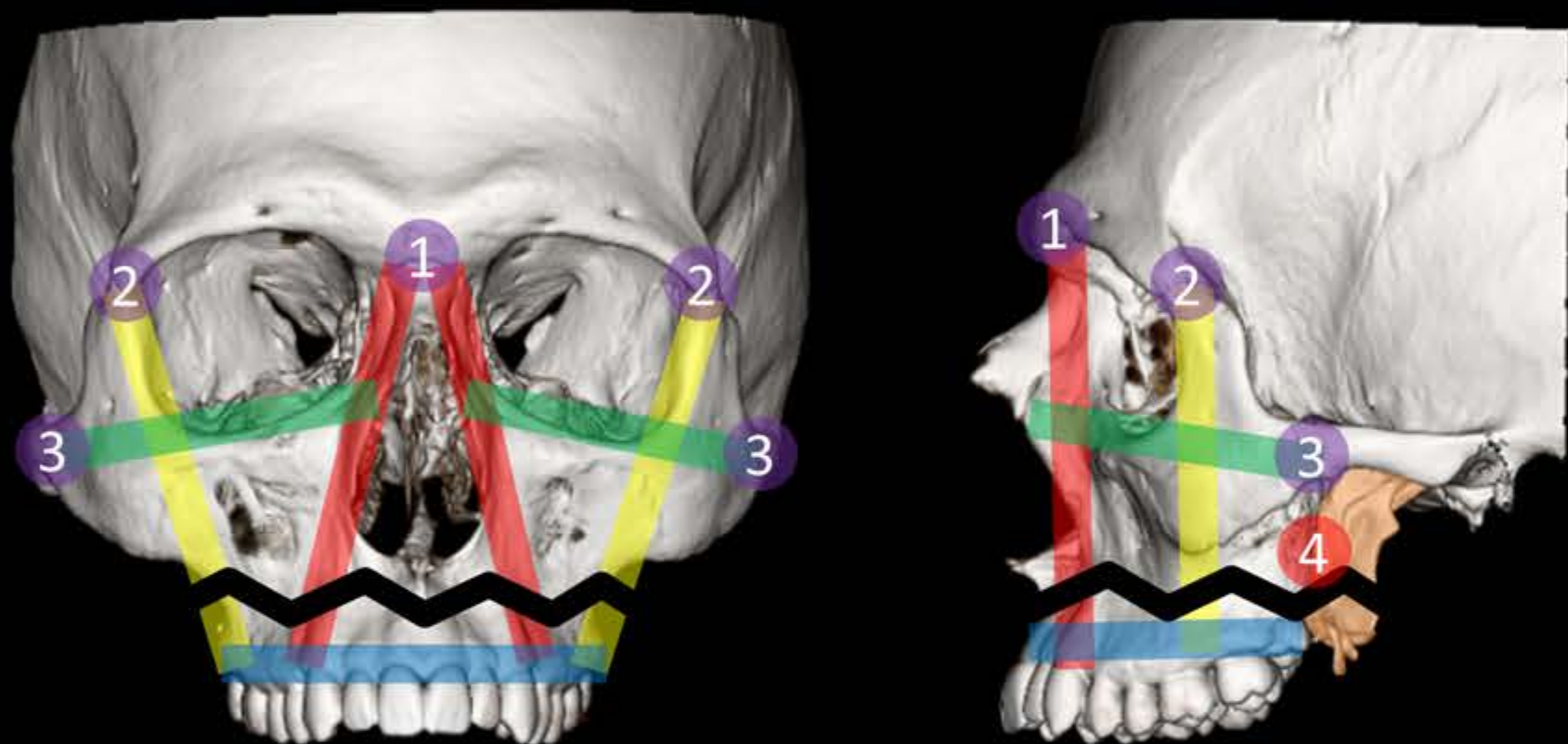
- Bones fractured**
  - Zygoma/zygomatic arch
  - Lateral and inferior orbital walls
  - Anterior and posterior walls of the maxillary sinus
- anchors disrupted**
  - Zygomaticofrontal
  - Zygomaticotemporal

(also, the zygomaticomaxillary and zygomaticosphenoid sutures are typically disrupted, rounding out the so-called tetrapod fracture)

### Surgical Repair

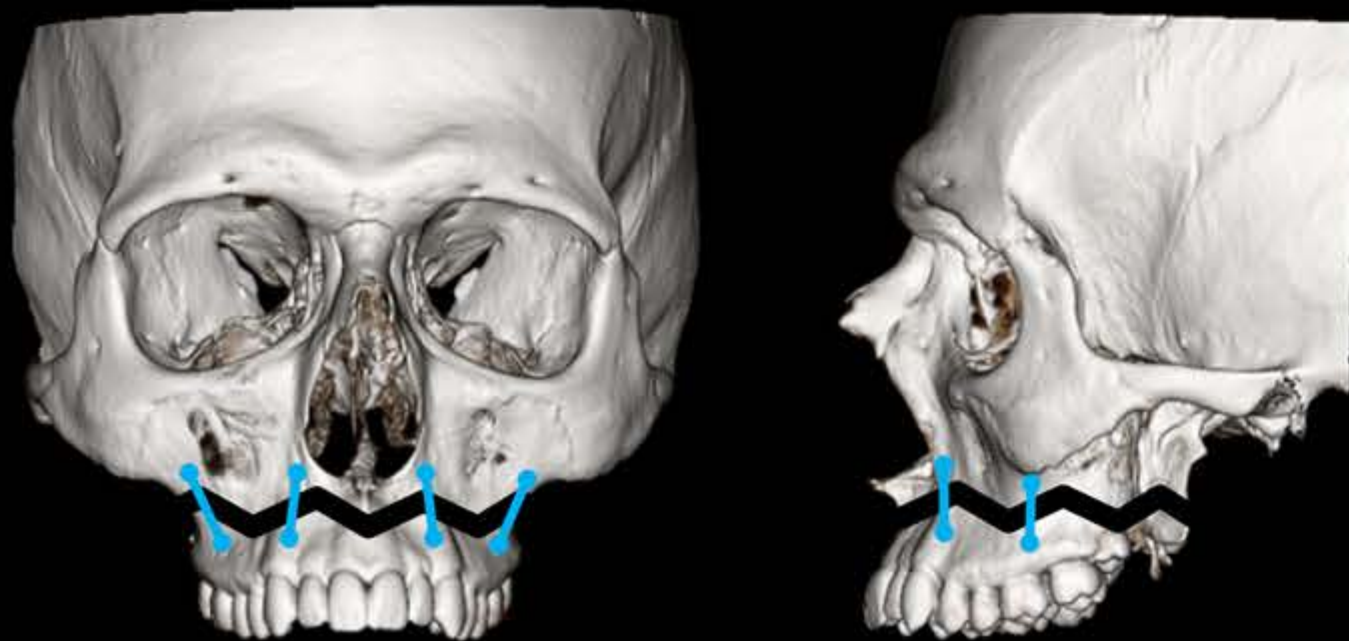


## Le Fort I

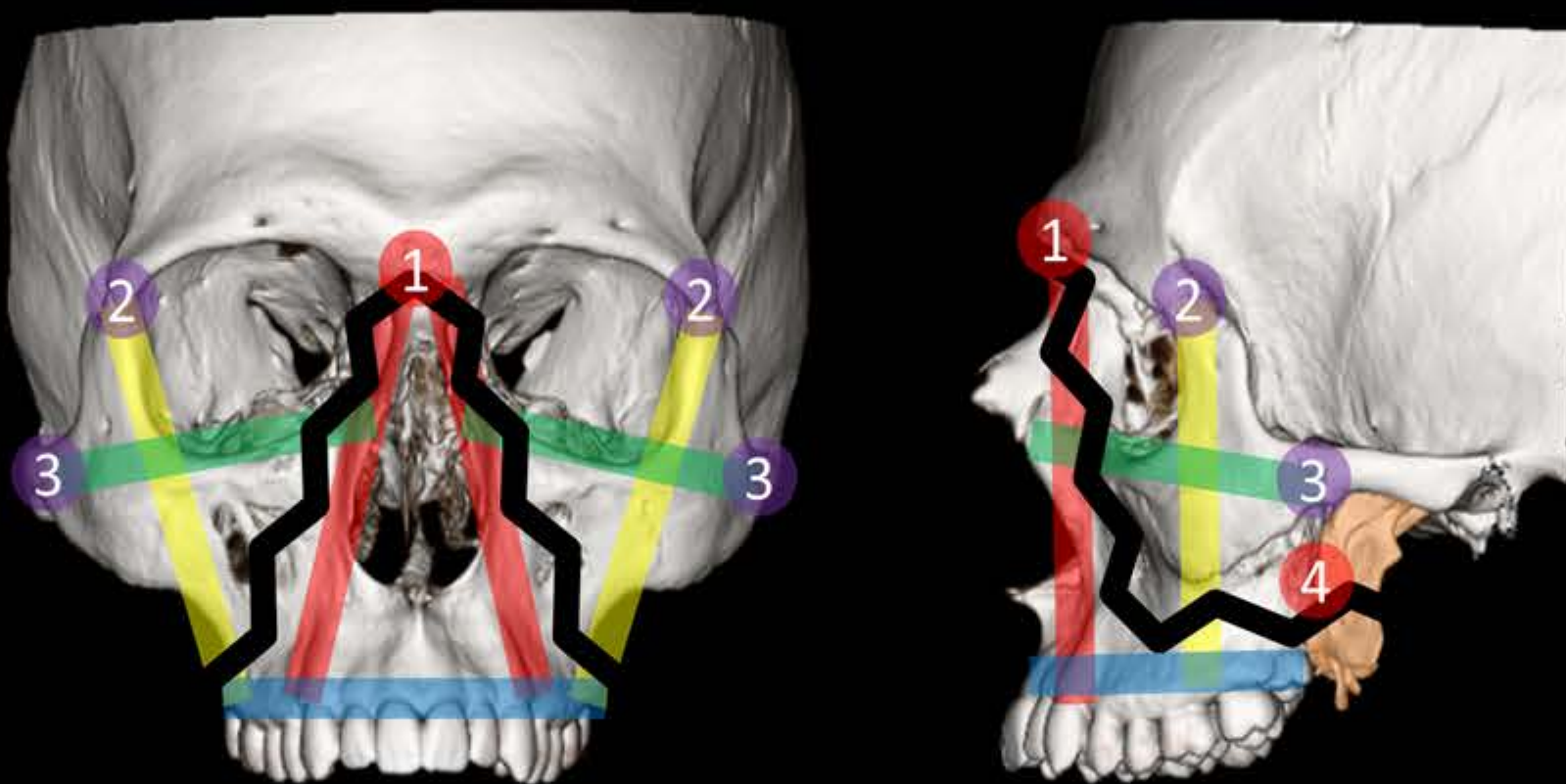


- Bones fractured**
  - Anterior, medial, lateral maxillary wall
  - Inferior margin of the piriform aperture and nasal septum
  - Pterygoid plates
- anchors disrupted**
  - Pterygomaxillary/pterygopalatine

### Surgical repair

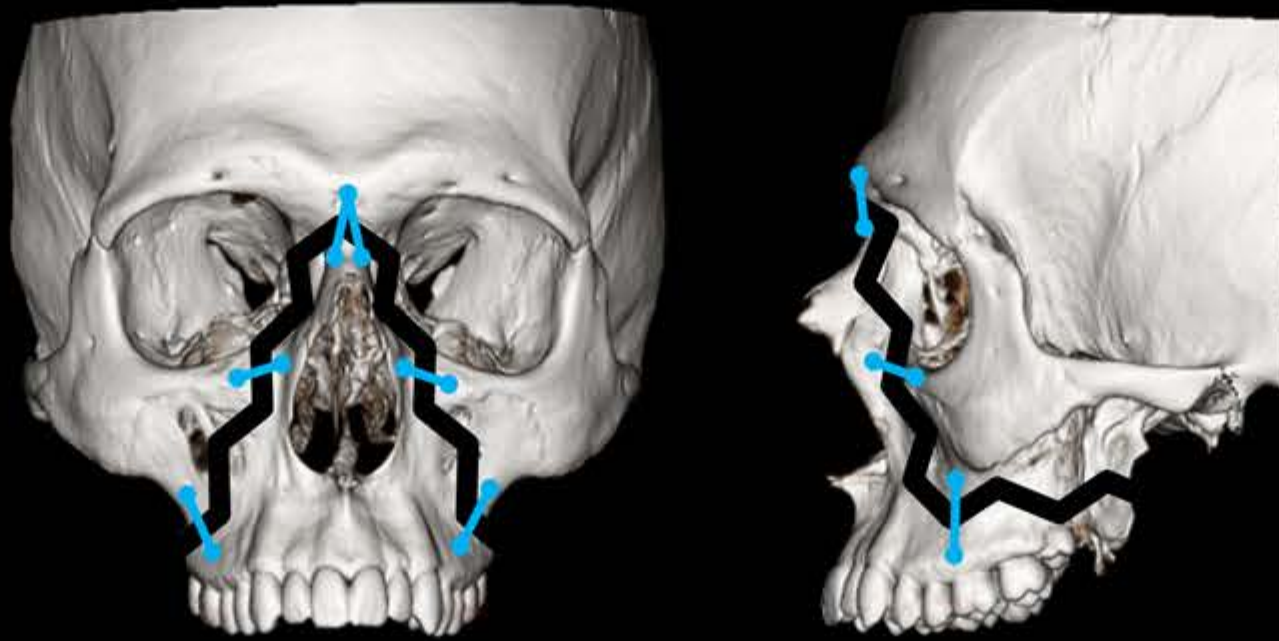


## Le Fort II

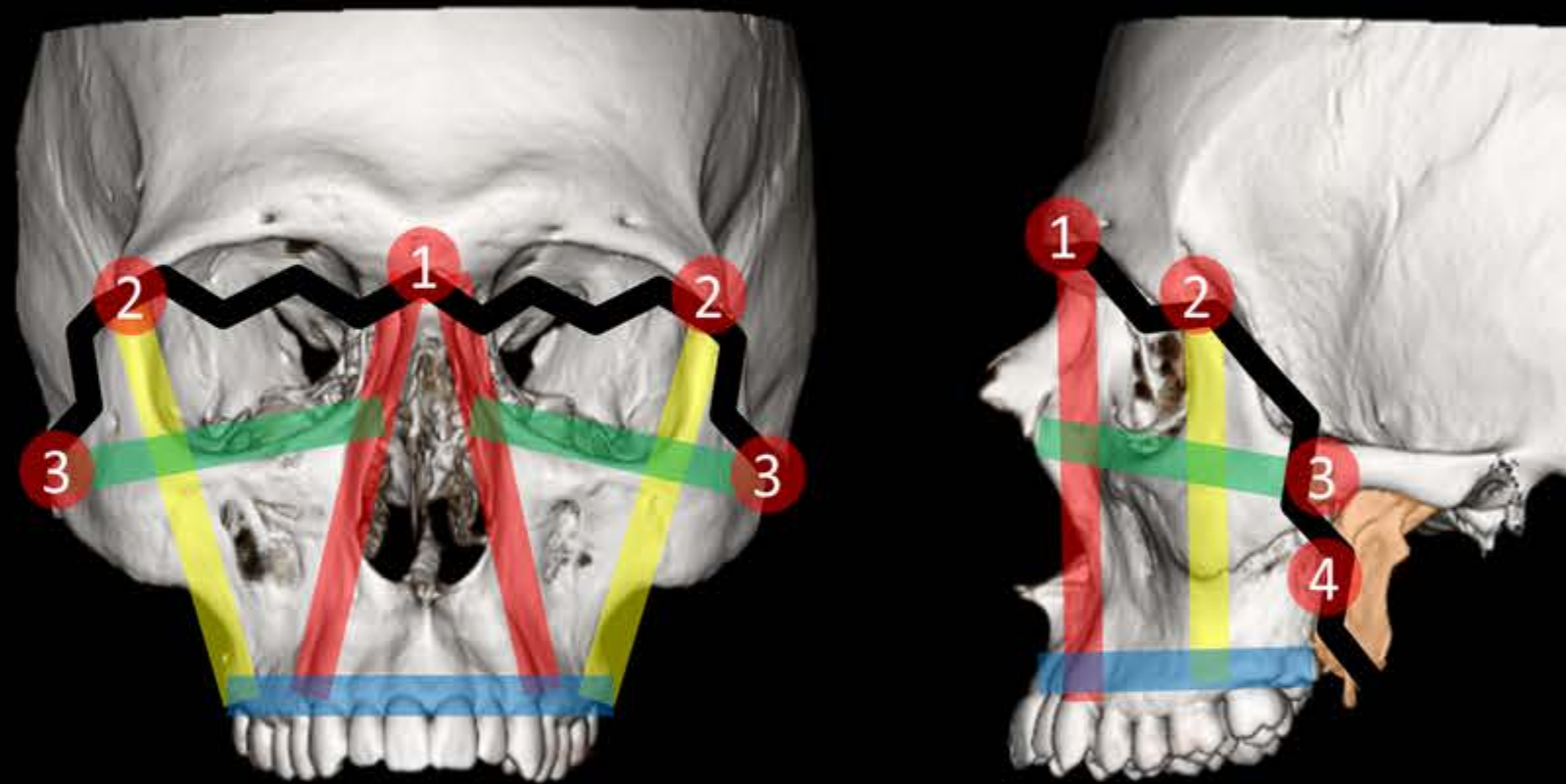


- Bones fractured**
  - Nasal bone/nasofrontal suture
  - Medial and inferior orbital wall
  - Lateral wall ± floor of the maxillary sinus
  - Pterygoid plates
- anchors disrupted**
  - Pterygomaxillary/pterygopalatine
  - Nasofrontal

### Surgical Repair



## Le Fort III



- Bones fractured**
  - Nasal bone/nasofrontal suture
  - Medial and lateral orbital wall
  - Zygomatic bone/zygomaticofrontal suture
  - Pterygoid plates
- anchors disrupted**
  - Pterygomaxillary/pterygopalatine
  - Nasofrontal
  - Zygomaticofrontal
  - Zygomaticotemporal

### Surgical Repair

